

RESEARCH

Impact of left ventricular outflow tract flow acceleration on aortic valve area calculation in patients with aortic stenosis

Andaleeb A Ahmed MD MPH¹, Robina Matyal MD², Feroze Mahmood MD², Ruby Feng BA², Graham B Berry MD², Scott Gilleland MD² and Kamal R Khabbaz MD³

¹Department of Anesthesiology, Lahey Hospital and Medical Center, Burlington, Massachusetts, USA

²Department of Anesthesia Critical Care and Pain Medicine, Beth Israel Deaconess Medical Center, Harvard Medical School, Boston, Massachusetts, USA

³Division of Cardiac Surgery, Department of Surgery, Beth Israel Deaconess Medical Center, Harvard Medical School, Boston, Massachusetts, USA

Correspondence should be addressed to A A Ahmed: andaleeb.a.ahmed@lahey.org

Abstract

Objective: Due to its circular shape, the area of the proximal left ventricular tract (PLVOT) adjacent to aortic valve can be derived from a single linear diameter. This is also the location of flow acceleration (FA) during systole, and pulse wave Doppler (PWD) sample volume in the PLVOT can lead to overestimation of velocity (V_1) and the aortic valve area (AVA). Therefore, it is recommended to derive V_1 from a region of laminar flow in the elliptical shaped distal LVOT (away from the annulus). Besides being inconsistent with the assumptions of continuity equation (CE), spatial difference in the location of flow and area measurement can result in inaccurate AVA calculation. We evaluated the impact of FA in the PLVOT on the accuracy of AVA by continuity equation (CE) in patients with aortic stenosis (AS).

Methods: CE-based AVA calculations were performed in patients with AS once with PWD-derived velocity time integral (VTI) in the distal LVOT (VTI_{LVOT}) and then in the PLVOT to obtain a FA velocity profile (FA- VTI_{LVOT}) for each patient. A paired sample *t*-test ($P < 0.05$) was conducted to compare the impact of FA- VTI_{LVOT} and VTI_{LVOT} on the calculation of AVA.

Result: There were 46 patients in the study. There was a 30.3% increase in the peak FA- VTI_{LVOT} as compared to the peak VTI_{LVOT} and AVA obtained by FA- VTI_{LVOT} was 29.1% higher than obtained by VTI_{LVOT} .

Conclusion: Accuracy of AVA can be significantly impacted by FA in the PLVOT. LVOT area should be measured with 3D imaging in the distal LVOT.

Key Words

- ▶ aortic valve area
- ▶ flow acceleration
- ▶ left ventricular outflow tract
- ▶ aortic stenosis
- ▶ echocardiography
- ▶ continuity equation

Introduction

Doppler-based calculation of aortic valve area (AVA) is based on multiple assumptions of geometry and flow through the left ventricular outflow tract (LVOT) and the aortic valve (AV) (1, 2, 3, 14, 15, 16, 17). In continuity equation (Fig. 1) LVOT area, continuous wave Doppler (CWD)-derived peak transaortic velocity (V_2) and pulse wave Doppler (PWD) derived peak LVOT velocities (V_1)

are used to calculate AVA (Fig. 1). Ratio V_1 and V_2 is also used to derive the 'dimensionless index' for aortic stenosis (AS) severity assessment. Due to its circular shape the proximal LVOT (PLVOT) adjacent to the aortic valve (AV) is the recommended site for diameter-derived LVOT area estimation (1, 2, 9, 10, 13). It is now known that the LVOT assumes an elliptical shape distally toward the left

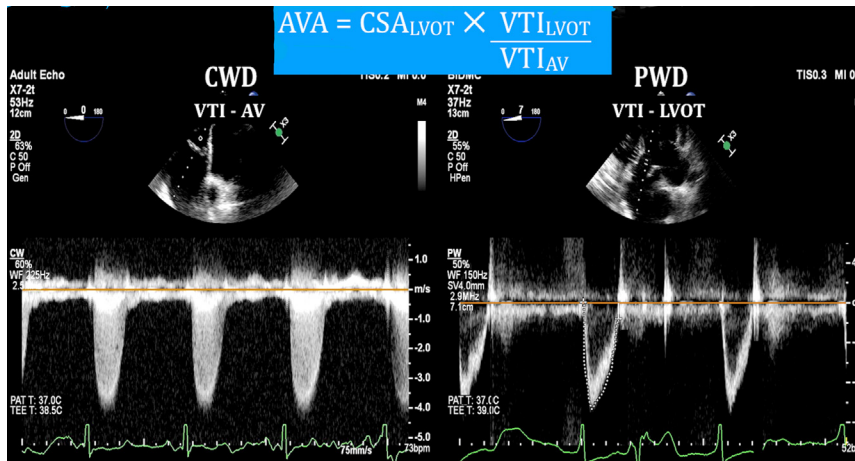


Figure 1

Doppler based calculation of aortic valve area using continuity equation. AV, aortic valve; AVA, aortic valve area; CSA, cross-sectional area; CWD, continuous wave Doppler; LVOT, left ventricular outflow tract; PWD, pulse wave Doppler; VTI, velocity time integral.

ventricle (DLVOT) (Fig. 2) (8). With PLVOT being the zone of flow acceleration (FA) (Figs 3 and 4), the guidelines recommend placement of the PWD sample volume 1 cm distal to the aortic leaflets in the DLVOT for V_1 estimation due to laminar flow (1). The flow acceleration is believed to result in turbulence, aliasing and incorrect V_1 estimation. Whereas aliasing is self-evident, flow acceleration without aliasing has the potential to impact continuity equation-based calculations.

Both recommendations of locations for area and flow estimation are based on the erroneous assumption of uniformity of circular shape and laminarity of flow through the LVOT (Table 1). The variation in location of LVOT diameter measurement and flow assessment is also inconsistent with continuity equation's assumption of the same spatial location of both these measurements. Whereas the impact of flow acceleration on the PWD-derived V_1 is known, the magnitude on error introduced into AVA due to FA has not been systematically studied (2). With the expanding availability and eligibility of patients for percutaneous options for AVR, there are fewer indications of surgical AVR for mild-to-moderate AS; making accurate AVA calculation is an important clinical undertaking.

It would be clinically prudent to systematically evaluate and bring awareness to this important clinical caveat that can impact the accuracy of a commonly performed clinical hemodynamic calculation. Therefore, we decided to study the impact of flow acceleration in the LVOT on V_1 flow profile and the accuracy of echocardiographic AVA calculation in patients undergoing AVR at our medical center.

Materials and methods

This study was conducted as part of an ongoing prospective echocardiographic data collection in patients undergoing surgery with transesophageal echocardiography (TEE) with waiver of informed consent. The study was approved by the Committee on Clinical Investigation at Beth Israel Deaconess Medical Center. The data of patients undergoing elective AVR surgery for AS with or without coronary artery bypass graft (CABG) surgery (surgical, percutaneous) between July 2018 and December 2018 was analyzed. Patients with poor echocardiographic windows, Doppler misalignment $>15^\circ$, and those without a complete set of Doppler-derived flow profiles could not be obtained were excluded from the study. All echocardiographic data

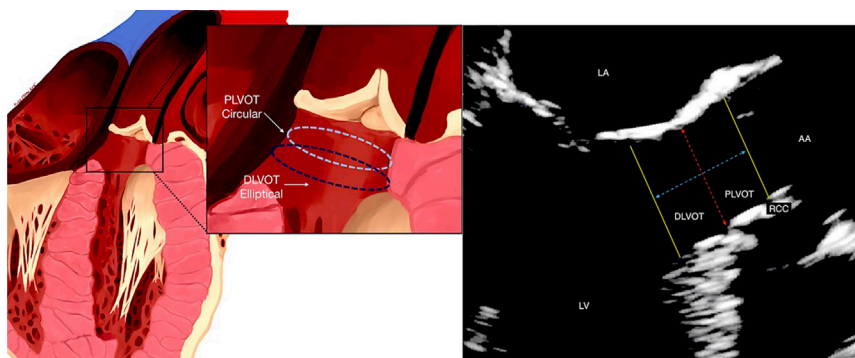


Figure 2

Artist's illustration of LVOT showing the heterogeneity of LVOT (left). Zoomed mid esophageal long axis view of the LVOT (right).

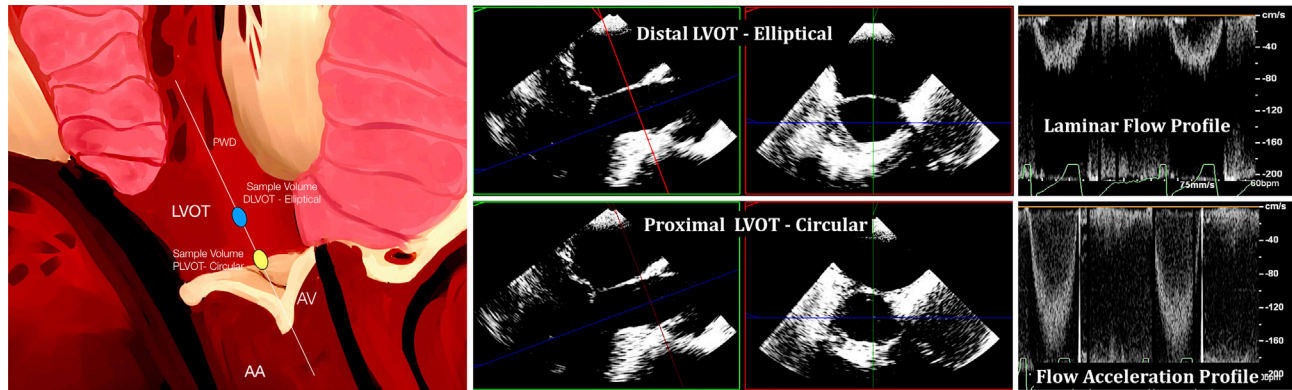


Figure 3

Artist's illustration of LVOT demonstrating the two sites of PWD sampling volume (left). 3D multi-planar reconstruction of the LVOT demonstrating the elliptical shape of distal LVOT (middle). PWD-based velocity profile of LVOT, demonstrating the 'step-up' seen as the sampling window is moved into the zone of flow acceleration (right). LVOT, left ventricular outflow tract; PWD, pulse wave Doppler.

were acquired using Philips iE-33 and EPIQ ultrasound systems with X7-2T TEE probes (Philips Medical Systems) and GE Vivid-E95 (General Electric Healthcare). All TEE studies were conducted immediately after the induction of general anesthesia and endotracheal intubation and prior to initiation of cardiopulmonary bypass. The TEE examination was carried out during a period of hemodynamic stability in the absence of background inotropic support or resuscitation. All examinations were either conducted by or under direct supervision of anesthesia staff members certified by the National Board of Echocardiography. Briefly the TEE examination was conducted in the following sequence:

- An initial comprehensive 2D TEE examination was carried out and all standard images were acquired and stored.
- The LVOT diameter was measured in the mid-esophageal long-axis view with appropriate depth and gain adjustments to obtain clear tissue margins. The linear measurement was made immediately below the insertion of the aortic leaflets in the annulus (PLVOT in Fig. 2).
- The TEE probe was then moved to the deep transgastric position to obtain a parallel Doppler alignment of the LVOT (Fig. 4).
- The PWD was used and the sample volume was placed 1 cm from the point of insertion of the AV leaflets to obtain a velocity profile (V_1) and its velocity time integral (VTI_{LVOT}) (Fig. 4).
- With the TEE probe in the deep transgastric position and the PWD activated, the PWD sample volume was gradually advanced toward the AV to achieve a 'step up' in the peak velocity (without aliasing), in the zone of flow acceleration to obtain a velocity profile ($FA-V_1$; $FA-VTI_{LVOT}$) (Fig. 4).
- The stored images were accessed from the ultrasound machine.
- Peak transaortic velocity (V_2), and its VTI (VTI_{AV}) were obtained by using continuous wave Doppler (CWD).
- An adequate flow profile was considered which demonstrated a clean velocity envelope with a clear peak velocity and edges without any spectral dispersion.
- 'Closing Click' was defined as a clear vertical line at the end of the PWD Doppler profile that signifies the closing of the AV (Fig. 4).

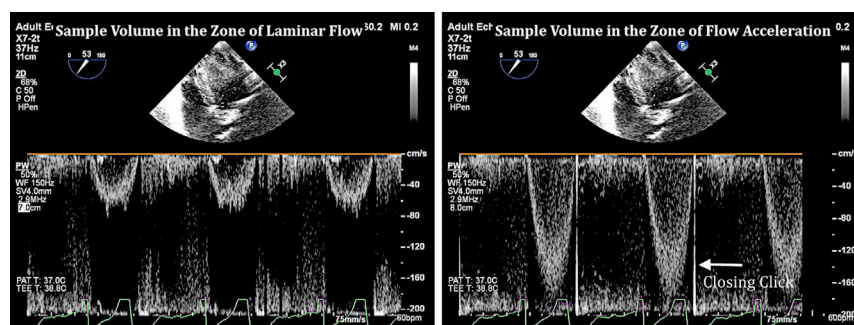


Figure 4

PWD-based velocity profile of LVOT demonstrating the phenomenon of flow acceleration (left). Aortic valve 'closing clicks' (right). PWD, pulse wave Doppler.

Table 1 Geometric and flow characteristics of LVOT (left ventricular outflow tract).

Proximal LVOT (near aortic valve)	Distal LVOT (away from aortic valve)
Likely to be circular in cross-section	Likely to be non-circular/elliptical in cross-section
Zone of flow acceleration	Zone of laminar flow
Recommended site for 2D LVOT diameter measurement	Recommended site for PWD-based VTI/velocity measurements

PWD, pulsed wave Doppler; VTI, velocity time integral.

- Aortic valve area was calculated using the VTI_{LVOT} and then $FA-VTI_{LVOT}$ in the continuity equation separately.
- In patients with atrial fibrillation the flow profiles were obtained three times and an average of the three was profiles was used for analysis.
- The studies were then retrieved at an offline echocardiographic viewing station and reviewed for accuracy by two examiners (FM and AA).
- A paired sample *t*-test ($P < 0.05$) was conducted to compare the peak LVOT velocities and calculated AVAs.
- The data were used for comparison only and were not used for clinical/surgical decision-making.

Results

Among the 57 patients who met the inclusion criteria, 11 were excluded due to incomplete or incorrect TEE measurements or poor-quality images. Our final dataset thus consisted of 46 patients. No patient in the final dataset had atrial fibrillation. Baseline demographic and echocardiographic characteristics are included in Table 2. Results are expressed as mean \pm s.d. Average LVOT diameter was 2.04 cm and average LVOT peak velocity (V_{LVOT}) was 0.786 m/s (Table 2). Average LVOT VTI (VTI_{LVOT}) was 21.24 cm. By placing the PW sampling volume in the zone of flow acceleration, the same measurements were made ($FA-V_1$; $FA-VTI_{LVOT}$). There was a 30.3% increase in peak LVOT velocity ($FA-V_1 = 1.095$, s.d. 0.27, CI: 0.08)

Table 2 Baseline demographic and echocardiographic characteristics.

Characteristics	n (%) or mean \pm s.d.
Male	26
Female	20
Age (years)	74.6 \pm 11.5
Body surface area index, m ²	1.98 \pm 0.25
Type of surgery	Percutaneous (TAVR): 26 Surgical: 20
Mean LVOT diameter (cm)	2.06 \pm 0.2
Peak transaortic velocity (V_2) (m/s)	3.87 \pm 0.58
Velocity time integral of AV (cm)	102.3 \pm 22.9

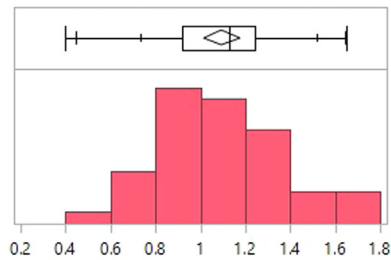
LVOT, left ventricular outflow tract; TAVR, transcatheter aortic valve replacement.

by alignment of PW sample volume in the zone of flow acceleration (Fig. 5). The average continuity equation-based aortic valve area using VTI_{LVOT} was 0.715 cm². By using $FA-VTI_{LVOT}$ (from flow acceleration zone), the average AVA was 0.923 cm² (s.d.: 0.29, CI: 0.08), which was 29.1% higher than the conventional AVA measurement (Fig. 6). By using the simplified continuity equation (using peak velocities instead of VTI), similar results were obtained. The average velocity and VTI ratios (dimensionless indices) were 0.20 and 0.21, and there was a 5% increase in these ratios when measured in the zone of flow acceleration (Table 3). Nine patients (19%) were re-classified from severe-to-moderate AS.

Discussion

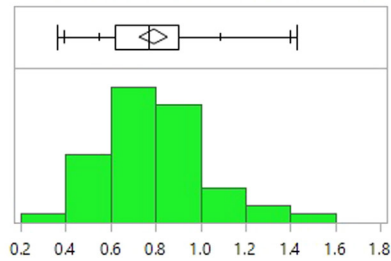
The results of our study demonstrate that flow acceleration in the LVOT can significantly impact the PWD-derived V_1 . Incorporation of the non-aliased LVOT velocities from the zone of flow acceleration, for AVA calculation results in significant overestimation (29.1% in absolute AVA value) of the AVA by the continuity equation and the dimensionless index. The overestimation of AVA is demonstrable using either the peak velocity or the VTIs from the zone of flow acceleration. Importantly, we have demonstrated that there can be a significant 'step-up' in the V_1 without any aliasing and that FA does not uniformly result in aliasing. Therefore, placement of PWD sample at the location of LVOT diameter measurement in the PLVOT that is most likely the zone of flow acceleration, can possibly result in a significantly higher V_1 and a larger AVA. Also, in majority of the cases the LVOT flow profile (from the zone of flow acceleration) could be distinguished from the non-flow acceleration V_1 with the presence of the closing click of the AV on the PWD-derived V_1 (Fig. 4). Whereas there was a significant overestimation of the AVA with LVOT flow acceleration, most AVA's in our series would still be classified as 'severe' AS. However, the magnitude of the absolute change in AVA with LVOT flow acceleration could possibly change the AVA severity classification in borderline cases with consequent impact on surgical decision-making.

▼ PWD derived peak LVOT velocity(meters/sec): Effect of flow acceleration (from PLVOT)



Peak LVOT velocity (meters/sec)	
Mean	1.0952174
Std Dev	0.2772944
Std Err Mean	0.0408848
Upper 95% Mean	1.1775637
Lower 95% Mean	1.0128711
N	46

▼ PWD derived peak LVOT velocity (meters/sec): No flow acceleration (from DLVOT)



Peak LVOT velocity (meters/sec)	
Mean	0.7913043
Std Dev	0.2093228
Std Err Mean	0.030863
Upper 95% Mean	0.8534655
Lower 95% Mean	0.7291431
N	46

Figure 5

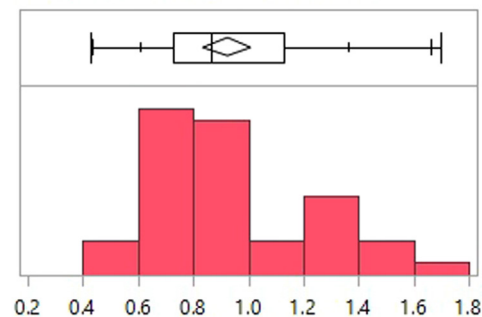
Effect of flow acceleration on peak LVOT velocity measurement (PWD based). DLVOT, distal LVOT (away from aortic annulus); PLVOT, proximal LVOT (near aortic annulus); PWD, pulse wave Doppler.

Since V_1 is derived in the region of laminar flow in the DLVOT, this should also be the site of cross-sectional area (CSA) measurement. Due to the elliptical shape of the DLVOT in majority, a planimetered 3D cross-sectional area should be used for continuity equation-derived calculations. A major limitation of this study was the lack of utilizing 3D planimetry for LVOT cross-sectional area

measurement and a lack of a control group presumably without LVOT flow acceleration.

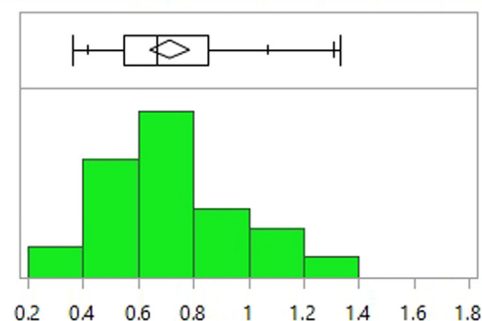
According to the guidelines, due to the circular shape of PLVOT a single linear diameter-derived area accurately represents the CSA of the PLVOT (4, 5, 6, 11). Being the zone of FA, positioning of the sample volume in the PLVOT results in a higher V_1 with introduction of error

▼ Continuity equation based AVA (cm2): Effect of LVOT flow acceleration



Aortic valve area (cm2)	
Mean	0.9226087
Std Dev	0.289547
Std Err Mean	0.0426914
Upper 95% Mean	1.0085936
Lower 95% Mean	0.8366238
N	46

▼ Continuity equation based AVA (cm2): No flow acceleration



Aortic valve area (cm2)	
Mean	0.7147826
Std Dev	0.2352468
Std Err Mean	0.0346853
Upper 95% Mean	0.7846423
Lower 95% Mean	0.6449229
N	46

Figure 6

Impact of LVOT flow acceleration on continuity equation based AVA measurement. AVA, aortic valve area; LVOT, left ventricular outflow tract.

Table 3 Impact of LVOT flow acceleration on commonly used echocardiographic parameters of aortic valve assessment.

Variable	Impact of LVOT flow acceleration	
	No flow acceleration	Zone of flow acceleration
Aortic valve area (cm ²)	0.715 ± 0.23	0.92 ± 0.29
LVOT peak velocity (V ₁)	0.79 ± 0.20	1.095 ± 0.27
LVOT VTI (cm)	21.5 ± 6.15	27.86 ± 7.75
Dimensionless index (VTI based)	0.217 ± 0.07	0.28 ± 0.085
Dimensionless index (V _{max} based)	0.20 ± 0.056	0.289 ± 0.077

LVOT, left ventricular outflow tract; VTI, velocity time integral.

in CE-derived calculations. Therefore, it is recommended that LVOT velocity should be obtained from a region of laminar flow in distal LVOT. Due to its elliptical shape, this location has a larger CSA than the proximal LVOT (Fig. 2) and a different flow profile. Three-dimensional (3D) imaging has demonstrated that assumptions of uniform geometry of LVOT have the potential to impact clinical decision-making (4, 5). Our study has demonstrated that besides the heterogeneity of structure, variation of flow in the LVOT also has the potential to significantly impact the results of CE. Hemodynamic calculations based on area of proximal LVOT that is circular and V₁ derived from distal LVOT that is elliptical do not conform to and are inconsistent with the basic assumptions of continuity equation and are prone to error (1, 2, 4, 5).

Stroke volume estimation via continuity equation is one of the most commonly performed echocardiographic calculations in the operating room. Inaccurate LVOT area calculation is considered the greatest source of error in stroke volume assessment and AVA calculation. Based on 3D imaging and Doppler-derived flow profiles, the heterogeneity of geometry and flow are established (Fig. 3 and 4) (4). To conform to the assumptions of continuity equation, the area and flow should be spatially measured at the same location. We have earlier demonstrated the heterogeneity of the structure of LVOT and its impact on the accuracy of AVA by CE (4). Our current study demonstrates the impact of flow acceleration on AVA calculation. Due to its elliptical shape a single linear diameter significantly underestimates the true area of distal LVOT. Therefore, 3D imaging should be routinely used to for derivation of a planimetered CSA of the distal LVOT for continuity equation. There has been controversy and debate about the discordance in various methods of AVA calculation (1, 12). The discordance has been attributed to methodological differences, variations in presumed

constants and loading conditions (2). Our study suggests that besides area, flow acceleration in the LVOT can also result in significant step up in the V₁ flow profile without aliasing. The presence of a closing click in the PWD flow profile is a reliable sign of a flow acceleration derived V₁, and it could be used as a guide to position the sample volume when using PWD for V₁.

Conclusion

In conclusion, due to variations in flow and heterogeneity of LVOT structure the current paradigm of spatial variation in area and flow estimation is inconsistent with the continuity equation. The spatial separation of area and flow measurement is based on an erroneous assumption of a uniformly circular LVOT and laminarity of flow. To avoid this inconsistency with the principles of flow dynamics and improving accuracy of hemodynamic data, 3D echocardiography (with multiplanar reconstruction) should be used to measure the distal LVOT where the flow is laminar and is the site of placement of the PWD sample volume.

Declaration of interest

The authors declare that there is no conflict of interest that could be perceived as prejudicing the impartiality of the research reported.

Funding

This research did not receive any specific grant from any funding agency in the public, commercial or not-for-profit sector.

References

- Baumgartner H, Hung J, Bermejo J, Chambers JB, Edvardsen T, Goldstein S, Lancellotti P, LeFevre M, Miller Jr F & Otto CM. Recommendations on the echocardiographic assessment of aortic valve stenosis: a focused update from the European Association of Cardiovascular Imaging and the American Society of Echocardiography. *Journal of the American Society of Echocardiography* 2017 **30** 372–392. (<https://doi.org/10.1016/j.echo.2017.02.009>)
- Hui S, Mahmood F & Matyal R. Aortic valve area-technical communication: continuity and Gorlin equations revisited. *Journal of Cardiothoracic and Vascular Anesthesia* 2018 **32** 2599–2606. (<https://doi.org/10.1053/j.jvca.2018.05.027>)
- Hahn RT, Nicoara A, Kapadia S, Svensson L & Martin R. Echocardiographic imaging for transcatheter aortic valve replacement. *Journal of the American Society of Echocardiography* 2018 **31** 405–433. (<https://doi.org/10.1016/j.echo.2017.10.022>)
- Montealegre-Gallegos M, Matyal R, Khabbaz KR, Owais K, Maslow A, Hess P & Mahmood F. Heterogeneity in the structure of the left ventricular outflow tract: a 3-dimensional transesophageal echocardiographic study. *Anesthesia and Analgesia* 2016 **123** 290–296. (<https://doi.org/10.1213/ANE.0000000000001439>)

- 5 Jainandunsing JS, Mahmood F, Matyal R, Shakil O, Hess PE, Lee J, Panzica PJ & Khabbaz KR. Impact of three-dimensional echocardiography on classification of the severity of aortic stenosis. *Annals of Thoracic Surgery* 2013 **96** 1343–1348. (<https://doi.org/10.1016/j.athoracsur.2013.05.018>)
- 6 Nishimura RA, Otto CM, Bonow RO, Carabello BA, Erwin JP III, Guyton RA, O’Gara PT, Ruiz CE, Skubas NJ, Sorajja P, et al. 2014 AHA/ACC guideline for the management of patients with valvular heart disease: a report of the American College of Cardiology/American Heart Association Task Force on Practice Guidelines. *Journal of the American College of Cardiology* 2014 **63** e57–e185. (<https://doi.org/10.1016/j.jacc.2014.02.536>)
- 7 Currie PJ, Seward JB, Reeder GS, Vlietstra RE, Bresnahan DR, Bresnahan JF, Smith HC, Hagler DJ & Tajik AJ. Continuous wave Doppler echocardiographic assessment of severity of calcific aortic stenosis: a simultaneous Doppler-catheter correlative study in 100 adult patients. *Circulation* 1985 **71** 1162–1169. (<https://doi.org/10.1161/01.cir.71.6.1162>)
- 8 Caballero L, Saura D, Oliva-Sandoval MJ, González-Carrillo J, Espinosa MD, García-Navarro M, Valdés M, Lancellotti P & de la Morena G. Three-dimensional morphology of the left ventricular outflow tract: impact on grading aortic stenosis severity. *Journal of the American Society of Echocardiography* 2017 **30** 28–35. (<https://doi.org/10.1016/j.echo.2016.10.006>)
- 9 Hatle L, Angelsen BA & Tromsdal A. Non-invasive assessment of aortic stenosis by Doppler ultrasound. *British Heart Journal* 1980 **43** 284–292. (<https://doi.org/10.1136/hrt.43.3.284>)
- 10 Oh JK, Taliercio CP, Holmes Jr DR, Reeder GS, Bailey KR, Seward JB & Tajik AJ. Prediction of the severity of aortic stenosis by Doppler aortic valve area determination: prospective Doppler-catheterization correlation in 100 patients. *Journal of the American College of Cardiology* 1988 **11** 1227–1234. ([https://doi.org/10.1016/0735-1097\(88\)90286-0](https://doi.org/10.1016/0735-1097(88)90286-0))
- 11 Vahanian A, Alfieri O, Andreotti F, Antunes MJ, Baron-Esquivias G, Baumgartner H, Borger MA, Carrel TP, De Bonis M, Evangelista A, et al. Guidelines on the management of valvular heart disease (version 2012). Joint Task Force on the Management of Valvular Heart Disease of the European Society of Cardiology (ESC); European Association for Cardio-Thoracic Surgery (EACTS). *European Heart Journal* 2012 **33** 2451–2496.
- 12 Baumgartner H, Hung J, Bermejo J, Chambers JB, Evangelista A, Griffin BP, Jung B, Otto CM, Pellikka PA, Quinones M, et al. Echocardiographic assessment of valve stenosis: EAE/ASE recommendations for clinical practice. *Journal of the American Society of Echocardiography* 2009 **22** 1–23; quiz 101. (<https://doi.org/10.1016/j.echo.2008.11.029>)
- 13 Smith MD, Kwan OL & DeMaria AN. Value and limitations of continuous-wave Doppler echocardiography in estimating severity of valvular stenosis. *JAMA* 1986 **255** 3145–3151.
- 14 Baumgartner H, Kratzer H, Helmreich G & Kuehn P. Determination of aortic valve area by Doppler echocardiography using the continuity equation: a critical evaluation. *Cardiology* 1990 **77** 101–111. (<https://doi.org/10.1159/000174590>)
- 15 Otto CM, Pearlman AS, Comess KA, Reamer RP, Janko CL & Huntsman LL. Determination of the stenotic aortic valve area in adults using Doppler echocardiography. *Journal of the American College of Cardiology* 1986 **7** 509–517. ([https://doi.org/10.1016/s0735-1097\(86\)80460-0](https://doi.org/10.1016/s0735-1097(86)80460-0))
- 16 Zoghbi WA, Farmer KL, Soto JG, Nelson JG & Quinones MA. Accurate noninvasive quantification of stenotic aortic valve area by Doppler echocardiography. *Circulation* 1986 **73** 452–459. (<https://doi.org/10.1161/01.cir.73.3.452>)
- 17 Skjaerpe T, Hegrenaes L & Hatle L. Noninvasive estimation of valve area in patients with aortic stenosis by Doppler ultrasound and two-dimensional echocardiography. *Circulation* 1985 **72** 810–818. (<https://doi.org/10.1161/01.cir.72.4.810>)

Received in final form 22 July 2019

Accepted 7 October 2019

Accepted Manuscript published online 7 October 2019